

BRIEF REPORT

Gene Therapy in a Patient with Sickle Cell Disease

Jean-Antoine Ribeil, M.D., Ph.D., Salima Hacein-Bey-Abina, Pharm.D., Ph.D., Emmanuel Payen, Ph.D., Alessandra Magnani, M.D., Ph.D., Michaela Semeraro, M.D., Ph.D., Elisa Magrin, Ph.D., Laure Caccavelli, Ph.D., Benedicte Neven, M.D., Ph.D., Philippe Bourget, Pharm.D., Ph.D., Wassim El Nemer, Ph.D., Pablo Bartolucci, M.D., Ph.D., Leslie Weber, M.Sc., Hervé Puy, M.D., Ph.D., Jean-François Meritet, Ph.D., David Grevent, M.D., Yves Beuzard, M.D., Stany Chrétien, Ph.D., Thibaud Lefebvre, M.D., Robert W. Ross, M.D., Olivier Negre, Ph.D., Gabor Veres, Ph.D., Laura Sandler, M.P.H., Sandeep Soni, M.D., Mariane de Montalembert, M.D., Ph.D., Stéphane Blanche, M.D., Philippe Leboulch, M.D., and Marina Cavazzana, M.D., Ph.D.

SUMMARY

Sickle cell disease results from a homozygous missense mutation in the β -globin gene that causes polymerization of hemoglobin S. Gene therapy for patients with this disorder is complicated by the complex cellular abnormalities and challenges in achieving effective, persistent inhibition of polymerization of hemoglobin S. We describe our first patient treated with lentiviral vector-mediated addition of an antisickling β -globin gene into autologous hematopoietic stem cells. Adverse events were consistent with busulfan conditioning. Fifteen months after treatment, the level of therapeutic antisickling β -globin remained high (approximately 50% of β -like-globin chains) without recurrence of sickle crises and with correction of the biologic hallmarks of the disease. (Funded by Bluebird Bio and others; HGB-205 ClinicalTrials.gov number, NCT02151526.)

The authors' affiliations are listed in the Appendix. Address reprint requests to Dr. Cavazzana at the Biotherapy Department, Necker Children's Hospital, Assistance Publique-Hôpitaux de Paris, 149 rue de Sèvres, 75015 Paris, France, or at m.cavazzana@aphp.fr; or to Dr. Leboulch at the Institute of Emerging Diseases and Innovative Therapies, 18, rte du Panorama BP-6, 92265 Fontenay-aux-Roses, France, or atpleboulch@rics.bwh.harvard.edu.

Drs. Ribeil and Hacein-Bey-Abina and Drs. Leboulch and Cavazzana contributed equally to this article

N Engl J Med 2017;376:848-55.

DOI: 10.1056/NEJMoa1609677

Copyright © 2017 Massachusetts Medical Society.

SICKLE CELL DISEASE IS AMONG THE MOST PREVALENT INHERITED MONOGENIC disorders. Approximately 90,000 people in the United States have sickle cell disease, and worldwide more than 275,000 infants are born with the disease annually.^{1,2} Sickle cell disease was the first disease for which the molecular basis was identified: a single amino acid substitution in “adult” β^A -globin (Glu6Val) stemming from a single base substitution (A→T) in the first exon of the human β^A -globin gene (*HBB*) was discovered in 1956.³ Sickle hemoglobin (HbS) polymerizes on deoxygenation, reducing the deformability of red cells. Patients have intensely painful vaso-occlusive crises, leading to irreversible organ damage, poor quality of life, and reduced life expectancy. Hydroxyurea, a cytotoxic agent that is capable of boosting fetal hemoglobin levels in some patients, is the only disease-modifying therapy approved for sickle cell disease.⁴

Allogeneic hematopoietic stem-cell transplantation currently offers the only curative option for patients with severe sickle cell disease.^{5,6} However, fewer than 18% of patients have access to a matched sibling donor.^{7,8} Therapeutic ex vivo gene transfer into autologous hematopoietic stem cells, referred to here as gene therapy, may provide a long-term and potentially curative treatment for sickle cell disease.⁹

We previously reported proof of effective, sustained gene therapy in mouse mod-

els of sickle cell disease by lentiviral transfer of a modified *HBB* encoding an antisickling variant ($\beta^{A87\text{Thr};\text{Gln} [\beta^{A-T87Q}]$).^{10,11} Here we report the results for a patient who received lentiviral gene therapy in the HGB-205 clinical study and who had complete clinical remission with correction of hemolysis and biologic hallmarks of the disease.

CASE REPORT

A boy with the β^S/β^S genotype, a single 3.7-kb α -globin gene deletion, and no glucose 6-phosphate dehydrogenase deficiency received a diagnosis of sickle cell disease at birth and was followed at the Reference Centre for Sickle Cell Disease of Necker Children's Hospital in Paris. He had a history of numerous vaso-occlusive crises, two episodes of the acute chest syndrome, and bilateral hip osteonecrosis. He had undergone cholecystectomy and splenectomy. During screening, a cerebral hypodensity without characteristics of cerebral vasculopathy was detected.

Because hydroxyurea therapy administered when the boy was between 2 and 9 years of age did not reduce his symptoms significantly, a prophylactic red-cell transfusion program was initiated in 2010, including iron chelation with deferasirox (at a dose of 17 mg per kilogram of body weight per day). He had had an average of 1.6 sickle cell disease-related events annually in the 9 years before transfusions were initiated.

In May 2014, he was enrolled in our clinical study. His verbal assent and his mother's written informed consent were obtained. In October 2014, when the patient was 13 years of age, he received an infusion of the drug product LentiGlobin BB305.

METHODS

STUDY OVERSIGHT

The study protocol, which is available with the full text of this article at NEJM.org, was designed by the last two authors and Bluebird Bio, the study sponsor. The protocol was reviewed by the French Comité de Protection des Personnes and relevant institutional ethics committees. Clinical data were collected by the first author, and laboratory data were generated by the sponsor, the last author, and other authors. The authors had access to all data, and data analysis was performed by them. The first author and one author employed by the sponsor wrote the first draft of the man-

uscript, which was substantively revised by the last two authors and further edited and approved by all the authors with writing assistance provided by an employee of the sponsor. The authors vouch for the accuracy and completeness of the data and adherence to the protocol.

ANTISICKLING GENE THERAPY VECTOR

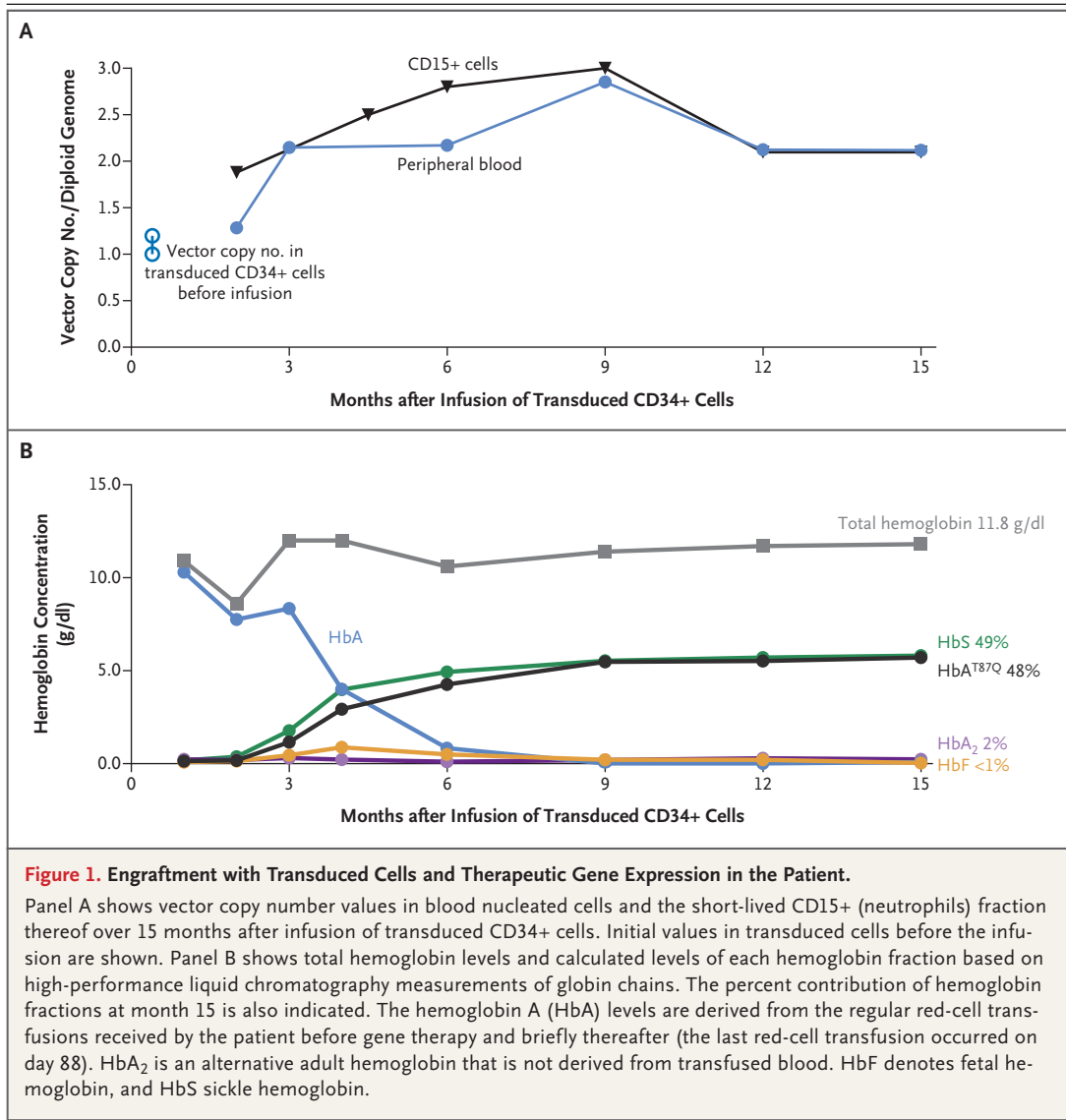
The structure of the LentiGlobin BB305 vector has been previously described (see Fig. S1 in the Supplementary Appendix, available at NEJM.org).¹² This self-inactivating lentiviral vector encodes the human *HBB* variant β^{A-T87Q} . In addition to inhibiting HbS polymerization, the T87Q substitution allows for the β -globin chain of adult hemoglobin (HbA)^{T87Q} to be differentially quantified by means of reverse-phase high-performance liquid chromatography.¹²

GENE TRANSFER AND TRANSPLANTATION PROCEDURES

Bone marrow was obtained twice from the patient to collect sufficient stem cells for gene transfer and backup (6.2×10^8 per kilogram and 5.4×10^8 per kilogram, respectively, of total nucleated cells obtained). Both procedures were preceded by exchange transfusion, and bone marrow was obtained without clinical sequelae. Anemia was the only grade 3 adverse event reported during these procedures. Bone marrow-enriched CD34+ cells were transduced with LentiGlobin BB305 vector (see the Methods section in the Supplementary Appendix).¹³ The mean vector copy numbers for the two batches of transduced cells were 1.0 and 1.2 copies per cell.

The patient underwent myeloablation with intravenous busulfan (see the Methods section in the Supplementary Appendix). The total busulfan area under the curve achieved was 19,363 μmol per minute. After a 2-day washout period, transduced CD34+ cells (5.6×10^6 CD34+ cells per kilogram) were infused. Red-cell transfusions were to be continued after transplantation until a large proportion of HbA^{T87Q} (25 to 30% of total hemoglobin) was detected.

The patient was followed for engraftment; toxic effects (graded according to the National Cancer Institute Common Terminology Criteria for Adverse Events, version 4.03); vector copy number in total nucleated blood cells and in different lineages; quantification of HbA^{T87Q}, HbS, and fetal hemoglobin levels by means of high-performance liquid chromatography; DNA integration-site map-



ping by linear amplification–mediated polymerase chain reaction in nucleated blood cells; and replication-competent lentivirus analysis by p24 antibody enzyme-linked immunosorbent assay. Red-cell analyses were performed at month 12 (see the Methods section in the Supplementary Appendix).

RESULTS

ENGRAFTMENT AND GENE EXPRESSION

Neutrophil engraftment was achieved on day 38 after transplantation, and platelet engraftment was achieved on day 91 after transplantation. Figure 1A shows the trajectory of vector copy numbers and Figure 1B shows production of HbA^{T87Q}. Gene

marking increased progressively in whole blood, CD15 cells, B cells, and monocytes (Fig. S2 in the Supplementary Appendix), stabilizing 3 months after transplantation. Increases in levels of vector-bearing T cells were more gradual.

HbA^{T87Q} levels also increased steadily (Fig. 1B) and red-cell transfusions were discontinued, with the last transfusion on day 88. Levels of HbA^{T87Q} reached 5.5 g per deciliter (46%) at month 9 and continued to increase to 5.7 g per deciliter (48%) at month 15, with a reciprocal decrease in HbS levels to 5.5 g per deciliter (46%) at month 9 and 5.8 g per deciliter (49%) at month 15. Total hemoglobin levels were stable between 10.6 and 12.0 g per deciliter after post-transplantation

month 6. Fetal hemoglobin levels remained below 1.0 g per deciliter.

SAFETY

The patient had expected side effects from busulfan conditioning. Grade 3 and 4 events included grade 4 neutropenia, grade 3 anemia, grade 3 thrombocytopenia, and grade 3 infection with *Staphylococcus epidermidis* (with positive results on blood culture), all of which resolved with standard measures. After the patient was discharged from the hospital, four grade 2 adverse events were reported: lower limb pain 3 months after treatment and transient increases in alanine aminotransferase, aspartate aminotransferase, and γ -glutamyltransferase between 5 and 8 months after treatment. All these events resolved spontaneously.

No adverse events related to the LentiGlobin BB305–transduced stem cells were reported (Table S1 in the Supplementary Appendix). Test results for the presence of replication-competent lentivirus were uniformly negative. Serial monitoring of integration sites in peripheral-blood samples showed a consistently polyclonal profile without detection of a dominant clone (defined as a single clone accounting for >30% of unique integration events) through month 12 (Fig. S3 in the Supplementary Appendix).

CLINICAL AND BIOLOGIC MEASURES

The patient was discharged on day 50. More than 15 months after transplantation, no sickle cell disease–related clinical events or hospitalization had occurred; this contrasts favorably with the period before the patient began to receive regular transfusions. All medications were discontinued, including pain medication. The patient reported full participation in normal academic and physical activities. Magnetic resonance imaging (MRI) of the head at 8 months showed unchanged punctate subcortical white-matter hypodensities. Lower limb MRI at 14 months showed no recent bone or tissue damage.

Changes in sickle cell disease–related biologic measures are shown in Table 1. Complete blood counts were stable, reticulocyte counts decreased substantially (Fig. S4 in the Supplementary Appendix), and circulating erythroblasts were not detected. Laboratory values, including urinary microalbumin levels, indicated normal renal and liver functions. Although iron chelation was discontinued before transplantation, the ferritin levels de-

Table 1. Key Laboratory Values before Gene Therapy (at Screening) and at 3-Month Intervals after Infusion of Transduced CD34+ Cells.

Measure	Normal Range	Screening*	Month 3†	Month 6	Month 9	Month 12	Month 15
Total hemoglobin (g/dl)	13.0–18.0	10.1	12.0	10.6	11.4	11.7	11.8
Red-cell count (per mm ³)	4,500,000–6,200,000	3,700,000	3,900,000	3,700,000	4,000,000	4,200,000	4,300,000
Reticulocyte count (per mm ³)	20,000–80,000*	238,000	259,000	132,000	131,000	143,000	141,000
Mean corpuscular hemoglobin (pg/red cell)	25–30	28	31	29	28	28	28
Mean corpuscular hemoglobin concentration (g/dl)	31–34	35	34	35	36	35	35
Platelet count (per mm ³)	150,000–450,000	356,000	52,000	122,000	157,000	168,000	201,000
Neutrophil count (per mm ³)	1500–7000	4200	2400	3100	2500	3000	2200
Total bilirubin (μ mol/liter)	0–17	50	15	20	14	12	12
Lactate dehydrogenase (U/liter)	125–243	626	285	254	226	274	212
C-reactive protein (ng/ml)	<500	191	814	129	ND	135	158
Ferritin (μ g/liter)	22–275	265	869	1095	ND	520	363
Transferrin (g/liter)	1.9–3.2	1.4	1.6	1.7	ND	1.5	1.7
Transferrin saturation (%)	16–35	72	ND	ND	35	56	40
Serum transferrin receptor (mg/liter)	0.8–1.7	5.7	3.0	2.3	ND	2.6	2.5
Iron (μ mol/liter)	12–30	26	18	14	ND	20	17
Hepcidin (ng/ml)	1–20	ND	ND	ND	ND	12.9	19.9
Alanine aminotransferase (U/liter)	5–45	22	76	125	116	53	41
Aspartate aminotransferase (U/liter)	5–40	53	57	71	50	49	35

* Exchange transfusion was performed before gene therapy was initiated, and supportive red-cell transfusions were completely discontinued 88 days after transplantation. ND denotes not done.

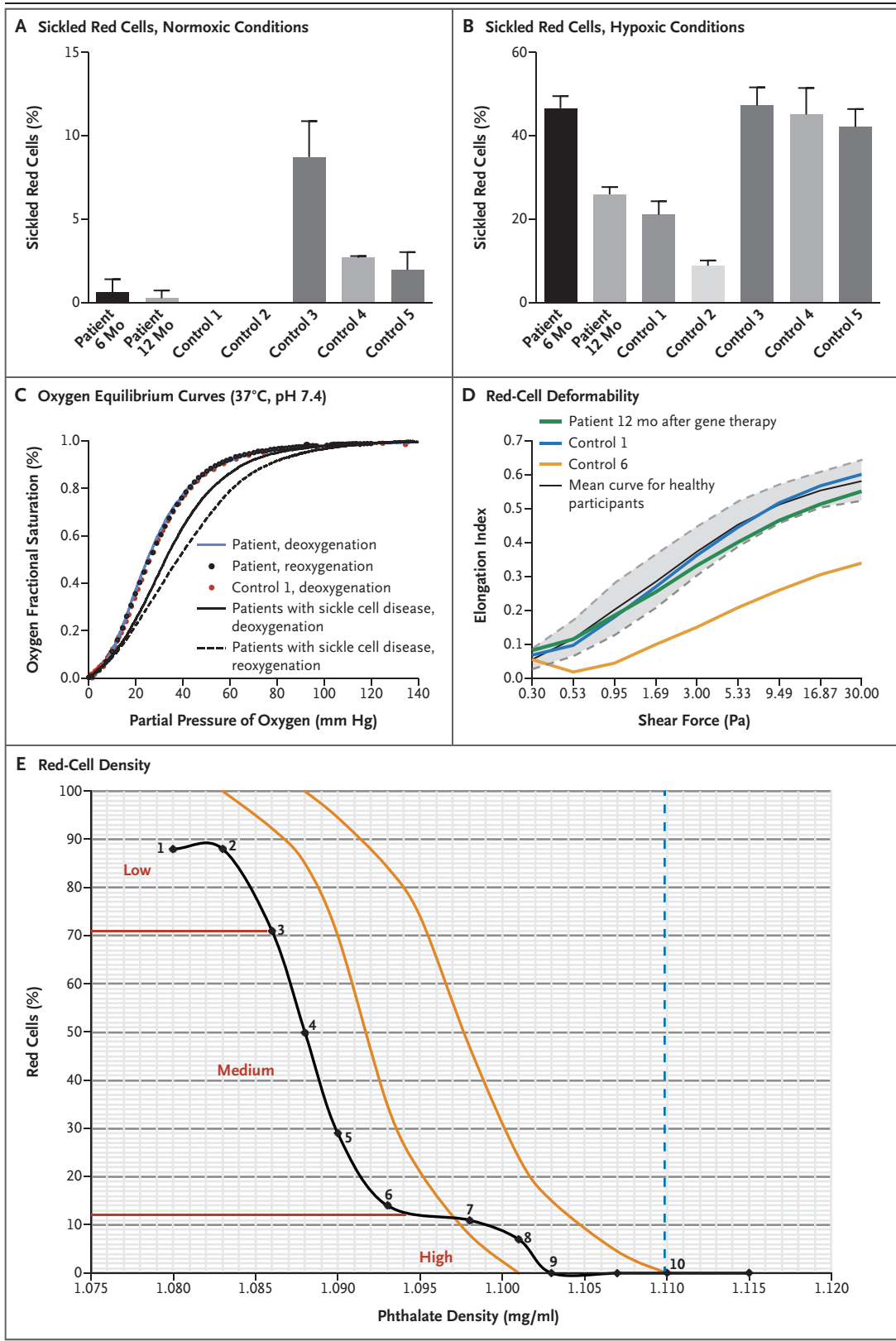


Figure 2 (facing page). Results of Sickle Cell Disease–Specific Red-Cell Assays.

Panel A shows rates of red-cell sickling under normoxic conditions (20% oxygen saturation) and Panel B shows rates of red-cell sickling under hypoxic conditions (10% oxygen saturation) in the patient at 6 months and 12 months after gene therapy and among control patients from whom red-cell samples were obtained: two patients with heterozygous A/S “sickle trait” (Controls 1 and 2; Control 1 is the patient’s mother) and three patients with sickle cell disease (Controls 3, 4, and 5). Similar results were obtained at 7% and 5% oxygen saturation rates (data not shown). T bars indicate standard errors. Panel C shows oxygen dissociation curves for red cells 12 months after gene therapy in the patient and in the patient’s heterozygous (A/S) mother (Control 1). These analyses were performed simultaneously, under identical conditions. The mean red-cell deoxygenation curve (solid black line) and the mean red-cell reoxygenation curve (dashed black line) for 15 untreated patients with sickle cell disease are also shown. Panel D shows red-cell deformability 12 months after gene therapy in the patient as compared with his heterozygous (A/S) mother (Control 1) and another patient with sickle cell disease (Control 6). The gray zone demarcates the range within which 95% of non-sickle cell disease red cells fall, and the black curve is the mean curve for healthy participants. The elongation index was calculated as the ratio of the length (A) and width (B) of a cell, where $(A-B)$ was divided by $(A+B)$, and the result was expressed as a decimal between 0 and 1. Panel E shows the red-cell density profile 12 months after gene therapy in the patient, obtained with the use of a phthalate gradient. We measured 10 samples (indicated with the numbers 1 through 10 on the black curve) at various phthalate densities. Red lines demarcate three different densities of cells: low (<1.086 mg per milliliter), medium (1.086 to 1.096 mg per milliliter), and high (>1.096 mg per milliliter). Orange lines indicate limits of a normal profile. The values for the patient are shifted to the left because of the associated single α -globin gene deletion. Cells denser than 1.110 mg per milliliter of phthalate solution are considered to be dense cells.

creased to 363 μg per liter at month 15, and MRI of the liver 1 year after treatment showed a low iron load (level of mobilizable circulating iron, relaxation rate $R2^* = 117$ Hz; and iron level, 3.1 mg per gram vs. 54 Hz and 14.6 mg per gram before gene therapy). Plasma levels of total bilirubin and lactate dehydrogenase normalized. Soluble transferrin receptor levels improved and were 3.4 times as high as normal values at screening and 1.5 times as high at months 12 and 15, indicating progressive normalization of erythropoiesis.

Because the patient received a regular transfusion regimen for 4 years before this study and because of the exchange transfusion before transplantation, meaningful comparative studies before and after transplantation could not be conducted. However, the proportions of sickled red cells in the patient’s blood at months 6 and 12 were significantly lower than those in untreated patients with sickle cell disease (β^S/β^S) (Fig. 2A). At month 12, the sickling rate in hypoxic conditions was not significantly different from that of the patient’s asymptomatic, heterozygous (β^A/β^S) mother (Fig. 2B). Oxygen dissociation studies, which quantify oxygen saturation relative to the partial pressure of oxygen, showed that results in the patient at month 12 and results in a heterozygous (β^A/β^S) control were similar (Fig. 2C and 2D).

DISCUSSION

This case report of a patient with sickle cell disease who received gene therapy with the use of lentiviral gene addition of an antisickling β -globin variant provides proof of concept for this approach and may help to guide the design of future clinical trials of gene therapy for sickle cell disease. Once the transduced stem cells engrafted, normal blood-cell counts were ultimately attained in all lineages. Increasing levels of vector-bearing nucleated cells in the blood over the first 3 months after transplantation and general vector copy number stability through month 15 suggest engraftment of transduced stem cells that were capable of long-term repopulation. No adverse events that were considered by the investigators to be related to the BB305-transduced cells were observed, and the pattern of vector integration remained polyclonal without clonal dominance.¹⁴

Insertional oncogenesis has been reported in clinical gene-transfer studies with gamma retroviral vectors but not with lentiviral vectors.^{15,16} Unlike gamma retroviruses, lentivirus tends to insert in transcriptionally active regions rather than near transcriptional start sites.¹⁷ In addition, the BB305 vector is an enhancer-deleted vector and is self-inactivating.¹² Reported data from this and other ongoing studies of the BB305 vector involving patients with sickle cell disease (7 patients) and β -thalassemia (22 patients) show a consistent safety profile, with no evidence of insertional mutagenesis through 4 to 30 months.^{18,19}

The appearance of vector-bearing cells in the periphery corresponds to the time frame for engraftment of long-term progenitors and stem cells repopulating the space of nucleated cells. In contrast, the slower pace for the increase of HbA^{T87Q} expression reflects the more gradual time course of replacement of transfused red cells from the pretransplantation and peritransplantation periods by newly matured, graft-derived red cells.

In mouse models of sickle cell disease, therapeutic globin expression after gene addition was difficult to obtain, presumably because of competition with endogenous β -globin messenger RNAs.¹¹ In the current study, a high concentration of therapeutic HbA^{T87Q} (ratio of HbA^{T87Q} to HbS, approximately 1) was achieved.^{10,11} HbA^{T87Q} expression appears to be sufficient to suppress hemolysis, resulting in stable hemoglobin concentrations of 11 to 12 g per deciliter and major improvement in all measurable sickle cell disease–specific biologic markers and blocking sickle cell disease–related clinical events.^{20,21}

Additional data on LentiGlobin treatment in sickle cell disease is currently being collected in HGB-206, a multicenter, phase 1/2 clinical study in the United States.¹⁹ Follow-up is more limited for these patients than for the patient in our study, but initial reports in seven patients have not included any new safety findings.¹⁹ Gene-transfer efficiency was lower than reported here, although therapeutic gene expression remained correlated with vector copy number values.

Outcomes in this patient provide further supportive evidence to our previously reported results of patients who underwent a similar ex vivo gene

therapy procedure for β -thalassemia with the same BB305 vector^{22,23} or the previous HPV569 vector.^{23,24} In addition to the patient with sickle cell disease described here, under this same clinical protocol, 4 patients with transfusion-dependent β -thalassemia have received LentiGlobin BB305. These participants had no clinically significant complications and no longer require regular transfusions.²² These findings are consistent with early results reported with 18 other patients with thalassemia who received LentiGlobin BB305 in clinical study HGB-204.²³ Longer follow-up is required to confirm the durability of the efficacy and safety profile observed, and data from additional evaluations of gene therapy in a larger cohort of patients to confirm the promise of gene therapy for sickle cell disease are lacking.

Supported by Bluebird Bio and by a grant to the Biotherapy Clinical Investigation Center from Assistance Publique–Hôpitaux de Paris and INSERM.

Disclosure forms provided by the authors are available with the full text of this article at NEJM.org.

We thank the staff at Necker Children's Hospital for their important contributions to the care of the patient described in this article; our colleagues Zoubida Karim, Ph.D., of Université Paris Diderot, Laurent Kiger, Ph.D., and Marie Georgine Rakotoson, Ph.D., of Institut Mondor de Recherche Biomédicale, and Michel Bahuaud of Centre Hospitalier Universitaire Henri Mondor for their contributions to the study; Laurent Kiger for creating and analyzing the oxygen-binding curves; Marie Georgine Rakotoson for creating and analyzing the density curves; Michel Bahuaud for assessing the patient's enzyme levels; Frédéric Galacteros for providing data on normal enzyme levels in patients with sickle cell disease; Mohammed Asmal, M.D., Ph.D., David Davidson, M.D., Tara O'Meara, Lilian Yengi, Ph.D., and Philip Gregory, Ph.D., of Bluebird Bio for their contributions to the study design and execution and for their critical review of an earlier version of the manuscript; and Katherine Lewis, an employee of Bluebird Bio, for editorial support in preparation of an earlier version of the manuscript.

APPENDIX

The authors' affiliations are as follows: the Departments of Biotherapy (J.-A.R., A.M., E.M., L.C., M.C.), Clinical Pharmacy (P. Bourget), Pediatric Neuroradiology (D.G.), General Pediatrics (M.M.), and Pediatric Immunology–Hematology Unit (B.N., S.B.), Necker Children's Hospital, Assistance Publique–Hôpitaux de Paris (AP-HP), Biotherapy Clinical Investigation Center, Groupe Hospitalier Universitaire Ouest, AP-HP, INSERM (J.-A.R., A.M., E.M., L.C., L.W., M.C.), Unité de Technologies Chimiques et Biologiques pour la Santé, Centre National de la Recherche Scientifique Unité Mixte de Recherche 8258, INSERM Unité 1022, Faculté de Pharmacie de Paris, Université Paris Descartes, Chimie ParisTech (S.H.-B.-A.), Immunology Laboratory, Groupe Hospitalier Universitaire Paris-Sud, Hôpital Kremlin-Bicêtre, AP-HP, Le Kremlin-Bicêtre (S.H.-B.-A.), the Institute of Emerging Diseases and Innovative Therapies, Imagine Institute, Université Paris Descartes, Sorbonne Paris Cité University (M.S., B.N., L.W., M.C.), Mère-Enfant Clinical Investigation Center, Groupe Hospitalier Necker Cochin (M.S.), Université Paris Diderot, Sorbonne Paris Cité University, INSERM Institut National de Transfusion Sanguine, Unité Biologie Intégrée du Globule Rouge, Laboratoire d'Excellence GR-Ex (W.E.N.), and Laboratoires de Virologie, Hôpital Cochin (J.-F.M.), Paris, Atomic and Alternative Energy Commission, Université Paris-Sud, Fontenay-aux-Roses (E.P., Y.B., S.C., P.L.), Institut Mondor de Recherche Biomédicale, Equipe 2, Centre de Référence des Syndromes Drépanocytaires Majeurs, Centre Hospitalier Universitaire Henri Mondor, AP-HP, Laboratoire d'Excellence GR-Ex, Créteil (P. Bartolucci), and Université Paris Diderot, Sorbonne Paris Cité University, INSERM Unité 1149, Hôpital Louis-Mourier, AP-HP, Laboratoire d'Excellence GR-Ex, Colombes (H.P., T.L.) — all in France; Bluebird Bio, Cambridge (R.W.R., O.N., G.V., L.S., S.S.), and Brigham and Women's Hospital and Harvard Medical School, Boston (P.L.) — both in Massachusetts; and Ramathibodi Hospital, Mahidol University, Bangkok, Thailand (P.L.).

REFERENCES

1. Brousseau DC, Panepinto JA, Nimmer M, Hoffmann RG. The number of people with sickle-cell disease in the United States: national and state estimates. *Am J Hematol* 2010;85:77-8.
2. Modell B, Darlison M. Global epidemiology of haemoglobin disorders and derived service indicators. *Bull World Health Organ* 2008;86:480-7.
3. Ingram VM. A specific chemical difference between the globins of normal human and sickle-cell anaemia haemoglobin. *Nature* 1956;178:792-4.
4. Strouse JJ, Lanzkron S, Beach MC, et al. Hydroxyurea for sickle cell disease: a systematic review for efficacy and toxicity in children. *Pediatrics* 2008;122:1332-42.
5. Bernaudin F, Socie G, Kuentz M, et al. Long-term results of related myeloablative stem-cell transplantation to cure sickle cell disease. *Blood* 2007;110:2749-56.
6. Bhatia M, Walters MC. Hematopoietic cell transplantation for thalassemia and sickle cell disease: past, present and future. *Bone Marrow Transplant* 2008;41:109-17.
7. Krishnamurti L, Abel S, Maiers M, Flesch S. Availability of unrelated donors for hematopoietic stem cell transplantation for hemoglobinopathies. *Bone Marrow Transplant* 2003;31:547-50.
8. Mentzer WC, Heller S, Pearle PR, Hackney E, Vichinsky E. Availability of related donors for bone marrow transplantation in sickle cell anemia. *Am J Pediatr Hematol Oncol* 1994;16:27-9.
9. Malik P, Leboulch P. Genetically engineered cures: gene therapy for sickle cell disease. In: Pace B, ed. *Renaissance of sickle cell disease research in the genome era*. London: Imperial College Press, 2007: 295-310.
10. Takekoshi KJ, Oh YH, Westerman KW, London IM, Leboulch P. Retroviral transfer of a human beta-globin/delta-globin hybrid gene linked to beta locus control region hypersensitive site 2 aimed at the gene therapy of sickle cell disease. *Proc Natl Acad Sci U S A* 1995;92:3014-8.
11. Pawliuk R, Westerman KA, Fabry ME, et al. Correction of sickle cell disease in transgenic mouse models by gene therapy. *Science* 2001;294:2368-71.
12. Negre O, Bartholomae C, Beuzard Y, et al. Preclinical evaluation of efficacy and safety of an improved lentiviral vector for the treatment of β -thalassemia and sickle cell disease. *Curr Gene Ther* 2015; 15:64-81.
13. Negre O, Eggimann AV, Beuzard Y, et al. Gene therapy of the β -hemoglobinopathies by lentiviral transfer of the β (A(T87Q))-globin gene. *Hum Gene Ther* 2016;27: 148-65.
14. Montini E, Cesana D, Schmidt M, et al. The genotoxic potential of retroviral vectors is strongly modulated by vector design and integration site selection in a mouse model of HSC gene therapy. *J Clin Invest* 2009;119:964-75.
15. Hacein-Bey-Abina S, Garrigue A, Wang GP, et al. Insertional oncogenesis in 4 patients after retrovirus-mediated gene therapy of SCID-X1. *J Clin Invest* 2008;118:3132-42.
16. Howe SJ, Mansour MR, Schwarzwaelder K, et al. Insertional mutagenesis combined with acquired somatic mutations causes leukemogenesis following gene therapy of SCID-X1 patients. *J Clin Invest* 2008;118:3143-50.
17. Wu X, Li Y, Crise B, Burgess SM. Transcription start regions in the human genome are favored targets for MLV integration. *Science* 2003;300:1749-51.
18. Thompson AA, Kwiatkowski JL, Rasako J, et al. LentiGlobin gene therapy for transfusion-dependent β -thalassemia: update from the Northstar HGB-204 Phase 1/2 Clinical Study. Presented at the 58th Annual Meeting of the American Society of Hematology, San Diego, CA, December 3-6, 2016. abstract.
19. Kanter J, Walters MC, Hsieh M, et al. Interim results from a phase 1/2 clinical study of LentiGlobin gene therapy for severe sickle cell disease. Presented at the 58th Annual Meeting of the American Society of Hematology, San Diego, CA, December 3-6, 2016. abstract.
20. Alsultan A, Alabdulaali MK, Griffin PJ, et al. Sickle cell disease in Saudi Arabia: the phenotype in adults with the Arab-Indian haplotype is not benign. *Br J Haematol* 2014;164:597-604.
21. Walters MC, Patience M, Leisenring W, et al. Stable mixed hematopoietic chimerism after bone marrow transplantation for sickle cell anemia. *Biol Blood Marrow Transplant* 2001;7:665-73.
22. Cavazzana M, Ribeil JA, Payen E, et al. Outcomes of gene therapy for severe sickle disease and beta-thalassemia major via transplantation of autologous hematopoietic stem cells transduced ex vivo with a lentiviral beta AT87Q-globin vector. *Blood* 2015;126:202. abstract.
23. Walters MC, Rasko J, Hongeng S, et al. Update of results from the Northstar Study (HGB-204): a phase 1/2 study of gene therapy for beta-thalassemia major via transplantation of autologous hematopoietic stem cells transduced ex-vivo with a lentiviral beta AT87Q-globin vector (LentiGlobin BB305 drug product). *Blood* 2015;126:201. abstract.
24. Cavazzana-Calvo M, Payen E, Negre O, et al. Transfusion independence and HMGA2 activation after gene therapy of human β -thalassaemia. *Nature* 2010;467: 318-22.

Copyright © 2017 Massachusetts Medical Society.